



Oil Extract of Jintan Hitam (*Nigella sativa*) Solution Gastric Ulcer Diseases

Syamsu Rijal¹, Upik A Miskad², Husni Cangara³, Hasta Handayani Idrus⁴, Edward Pandu Wiriansyah⁵, Arina Fathiyah Arifin⁶

¹Departement of Hystology, Faculty of Medicine, Universitas Muslim Indonesia, Makassar, Indonesia

²Departement of Phatology Anatomy, Faculty of Medicine, Hasanuddin University, Makassar, Indonesia

³Departement of Phatology Anatomy, Faculty of Medicine, Hasanuddin University, Makassar, Indonesia

⁴Departement of Microbiology, Faculty of Medicine, Universitas Muslim Indonesia, Makassar, Indonesia

⁵Departement of Hystology, Faculty of Medicine, Universitas Muslim Indonesia, Makassar, Indonesia

⁶Departement of Hystology, Faculty of Medicine, Universitas Muslim Indonesia, Makassar, Indonesia

*Corresponding author: Syamsu Rijal, Affiliation, Universitas Muslim Indonesia, Makassar, Indonesia,

Abstract :Background and Aim: Gastric ulcer is the destruction of the mucosal layer to the muscularis mucosa that is round or oval > 5 mm in shape due to the continuity of the integrity of the gastric mucosa being cut off. The occurrence of gastric ulcers is caused by an imbalance between aggressive and protective factors, Helicobacter pylori, Non-Steroid Anti-Inflammatory Drugs (NSAIDs), alcohol consumption, and stress. The content of active substances in Jintan Hitam such as thymoquinone (30% -48%), thymohydroquinone, dithymoquinone, p-cymene (7% -15%), calvacrol (6% -12%), 4-terpineol (2% -7%) , t-anethol (1% -4%). Thymoquinone as a component derived from black cumin oil extract has the main molecular target as anti-oxidant and anti-inflammatory. Antioxidant effect through scavenging action, induces anti-oxidant enzymes, and improves mitochondrial function. As for TQ as an anti-inflammatory by reducing IL-1 β , and TNF- α , 5-LOX. **Conclusion:** Giving Jintan Hitam oil extract at the right dose is effective in reducing the incidence of gastric ulcers and there is no significant difference between giving Jintan Hitam oil extract and giving chemical treatment in the incidence of gastric ulcers. It is necessary to consider giving black cumin extract to patients with gastric ulcers who are allergic and resistant to chemical treatment.

Keywords - oil extract, jintan hitam (*nigella sativa*), gastric ulcer, herbal medicine

I. INTRODUCTION

Gastric Ulcer Treatment aims to reduce pain, treat ulcers, and prevent recurrent ulcers, as well as prevent them. This condition can only be achieved if there is a balance between aggressive factors (gastric acid and pepsin) and defensive factors of the gastric mucosa (mucus secretion, bicarbonate, epithelial regeneration, prostaglandins, and blood flow)[1]. Gastric ulcer is the destruction of the mucosal layer to the muscularis mucosa that is round or oval > 5 mm in shape due to the continuity of the integrity of the gastric mucosa being cut off. The occurrence of gastric ulcers is caused by an imbalance between aggressive and protective factors, Helicobacter pylori, Non-Steroid Anti-Inflammatory Drugs (NSAIDs), alcohol consumption, and stress[2].

The prevalence of gastric ulcers is influenced by socioeconomic, demographic, gender, and age. In the United States there are 4,000,000 people (12%) of cases of gastric ulcers, with 500,000 new cases. The use of drugs such as antacids, H2-receptor antagonists, Proton Pump Inhibitors, Anti-cholinergics, are less effective and cause many complications[3]. Commonly used antacids including calcium carbonate and sodium

bicarbonate with prolonged use of calcium carbonate can cause Burnett syndrome (hypercalcemia, hyperphosphatemia, possibly renal calcinosis and widespread renal insufficiency).

Sodium bicarbonate can induce systemic alkalosis[4]. *Nigella sativa* (*N. sativa*) or Habbah Al Sauda, in Indonesia called Jintan Hitam, is a plant used by residents in Saudi Arabia, Turkey, Syria, Pakistan, India, Southeast Asia as a plant to improve health, and a medicine to fight dyspepsia, jaundice, fever, anti-inflammatory, anti-oxidant, asthma, cancer, and antimicrobial[5].

The content of active substances in Jintan Hitam such as thymoquinone (30% -48%), thymohydroquinone, dithymoquinone, p-cymene (7% -15%), calvacrol (6% -12%), 4-terpineol (2% -7%), t-anethol (1% -4%). Thymoquinone as a component derived from black cumin oil extract has the main molecular target as anti-oxidant and anti-inflammatory[6]. Antioxidant effect through scavenging action, induces anti-oxidant enzymes, and improves mitochondrial function. As for TQ as an anti-inflammatory by reducing IL-1 β , and TNF- α , 5-LOX[7].

Research on the gastroprotective effect of *Nigella sativa* oil extract on gastric mucosa induced by acute ethanol has shown that the Thymoquinone (TQ) component can accelerate wound healing, increase Gastric Glutathione content (GSH), increase the activity of the enzyme Superoxide Dismutase (SOD), and Glutathione s-transferase. (GST). *Nigella sativa* is just as effective as Cimetidine in curing gastric ulcers, and can be given together in daily practice[8].

II. JINTAN HITAM (NIGELLA SATIVA)

Traditionally, black cumin seeds and oil are used for various diseases. Black cumin seeds are considered to have a bitter, spicy, aromatic, appetizer, stimulant, diuretic, emmenagogue, galactagogue, anthelmintic, spicy, thermogenic, carminative, pain reliever, deodorant, digestive, constipation, sudorific, fever-reducing drug, expectorant, laxative, abortion, ascites, cough, jaundice, rabies, paralysis, conjunctivitis, piles, skin disease, anorexia, dyspepsia, bloating, stomach upset, diarrhea, dysentery, intrinsic bleeding and amenorrhea[9]. Black Jintan oil is also used for local anesthesia. *Nigella sativa* in Indonesia is known as black cumin, while in Saudi Arabia *N. sativa* is known as Al-Habbah Al Sawda, Habbet El-Baraka, Kamoun Aswad, Schuniz and Khodria. In Pakistan India and Sri Lanka are known as Kalvanji, Kalunji, Azmut, Gurat, Aof and Aosetta. In English this plant is known as black seed, black cumin, black caraway, cinnamon flower, nutmeg flower and love-in-a-mist[10].

This plant is about 20-60 cm tall, short-lived, linear leaves grayish green, thin like threads. The seeds are rather hard, double pyramid with both ends tapered, one pyramid shorter than the other, angled 3 to 4, 1.5 mm to 2 mm long, 1 mm wide outer surface brownish black, black gray to black, mottled, rough, wrinkled, sometimes with multiple longitudinal or transverse ribs. In the cross-section of the seeds, the seed coat is blackish brown to black in color, the endosperm is reddish yellow, gray, or blackish gray. It has a very pungent odor, and contains about 21% protein, 35% carbohydrates and 35-38% plant fats and oils[11].



Figure 1 Jintan Hitam (*Nigella sativa*)[11]

III. GASTRIC HISTOLOGY

Macroscopically, the stomach consists of four parts; (1) Cardia, as a narrow area at the gastroesophageal boundary, 2-3 cm wide, (2) Fundus, a dome-shaped area on the left of the esophagus and often filled with gas, (3) The corpus, the largest part, which is responsible for forming the food bolus

(chyme).), (4) Pylorus, the part that is wrinkled, funnel-shaped, and equipped with a thick pyloric spinter to control the gradual release of food boluses into the duodenum. Histologically, the fundus and the macroscopic corpus are the same[12].

The mucosal folds, called rugae, disappear as the stomach expands. The stomach also has a gastric foveola, the superficial one in the fundus, and the deepest in the pylorus. The stomach is part of the digestive tract similar to a pocket. The resting state of the adult stomach volume is 50 ml, but when it contains food, it can accommodate about 1,500 ml[13]. The intraluminal pressure is relatively constant due to the influence of the hormone Ghrelin, which stimulates hunger and causes smooth muscle relaxation of the external muscles. Bolus (chyme) of food from the esophagus to the stomach and gradually to the duodenum through the pyloric valve in liquid form, which is assisted by stomach acid and various enzymes, namely Pepsin, Renin, Lipase, and paracrine hormones[14].

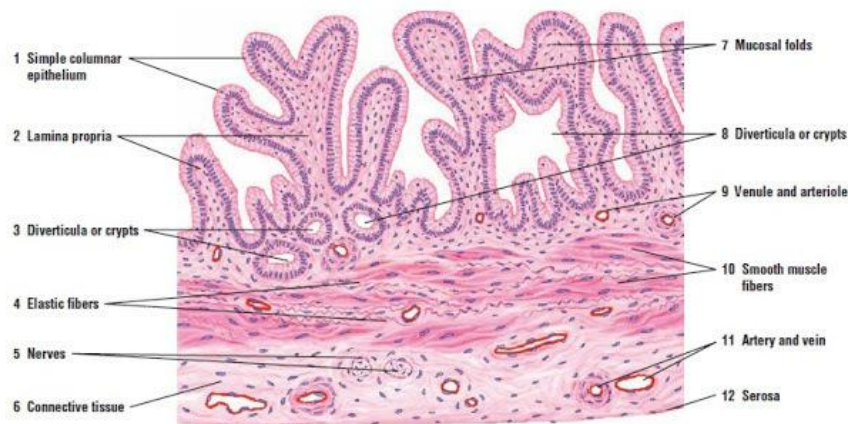

FIGURE 14.9 ■ Wall of gallbladder. Stain: hematoxylin and eosin. Low magnification.

Figure 2 Gastric Histology[14]

Gastric gland cells have the following main functions: (1) Neck mucosal cells are present in groups or individually among the parietal cells in the neck of the gastric gland. The shape is irregular, with the nucleus at the base of the cell and the secretory granules near the apical surface, and the mucus secretion is less alkaline. (2) Parietal cells are present in the upper half of the gastric gland, and a little at the base of the cell. Round or pyramidal shape with a round nucleus in the middle with eosinophilic cytoplasm. These cells secrete hydrochloric acid (HCl) and intrinsic factor (a glycoprotein required for uptake of vitamin B12 in the intestine. Parietal cells also have gastrin, histamine and acetylcholine receptors. (3) Zymogen cells (Chief cell) are many at the bottom of the tubular gland and contains the inactive pepsinogen enzyme. Turns into the proteolytic enzyme pepsin in an acidic stomach acid. (4) Enteroendocrine cells are cells that produce various hormones in the form of short polypeptides. These cells are not visible with HE staining These cells produce serotonin (5-hydroxytryptamine) (5) Stem cells, only a few and found in the neck of the gland. The defense system of the gastric mucosa consists of three components, namely: pre-epithelial, epithelial, and sub epithelial. The first line is the bicarbonate mucus layer, which functions as a physicochemical barrier against various molecules. including hydrogen ions[15][16].

Mucus is secreted by the surface epithelial cells of the gastroduodenum on a regular basis. Mucus is composed of 95% water, and a mixture of fat and glycoprotein (mucin). The mucus gel acts as a water layer that blocks the diffusion of ions and molecules such as pepsin. The bicarbonate that is secreted regularly will form a pH barrier of around 1-2, and reaches 6-7 along the surface epithelium[17]. Surface epithelial cells are the next line of defense because they are associated with several factors such as mucus formation, ion transport, epithelial cells that maintain pH and intracellular bicarbonate production. If the pre-epithelial barrier is disturbed, gastric epithelial cells that are around the injury site will migrate to restore the damaged site[18][19].

This process occurs independently of mitosis, requires blood flow, as well as the alkaline pH of the surrounding environment. Several factors that modulate the restitution process are epidermal growth factor, transforming growth factor, and fibroblast growth factor[20][21]. If a defect is larger and requires a cell regeneration process, the mechanism is through regulation of prostaglandins and growth factors, such as EGF and TGF- α . Together with the replacement of epithelial cells, there is the formation of new blood vessels (angiogenesis) which is regulated by the Vascular Endothelial Growth Factor. The subepithelial defense system is the microcirculation up to the submucosal layer, which produces HCO₃⁻ to neutralize the acid produced by parietal cells. In addition, microcirculation ensures adequate micronutrients and oxygen[22][23].

Physiology of Gastric Acid Secretion

Acid-producing parietal cells located in the oxytic glands express receptors for several acid-secreting stimulants, including histamine (H₂), gastrin (gastrin receptors) and acetylcholine, which are located in the basal part of the plasmalemma. The process of gastric acid production is as follows: (1) The enzyme carbonic anhydrase causes the production of carbonic acid (H₂CO₃) from water (H₂O) and CO₂ which then dissociates into hydrogen ions (H⁺) and bicarbonate (HCO₃⁻) in the cytoplasm of parietal cells. (2) Then H⁺, K⁺ + ATPase use adenosine triphosphate (ATP) as an energy source to pump intracellular H⁺ out of the cell into intracellular canaliculi and transfer extracellular K⁺ ions into the cell. (3) Proteins that use ATP as an energy source pump K⁺ and chloride (Cl⁻) ions out of the cell, into the intracellular canaliculus. So Cl⁻ and H⁺ enter the lumen of the intracellular canaliculus separately and combine in the cell to form HCl[24][25]. (5) K⁺ is actively transported into the cell through the cell membrane, as well as through the microvilli that protrude on the surface of the intracellular canaliculus, thereby increasing the K⁺ content. Increasing the K⁺ concentration forces the K⁺ ions out through the ion channel. (6) Water originating from the extracellular fluid enters the parietal cells and leaves the cytoplasm to enter the intracellular canaliculus which causes an increase in osmotic pressure, and the HCl formed by parietal cells enters the stomach[26][27][28].

Hydrochloric acid and pepsinogen are the two main secretory components of the stomach capable of injuring the mucosa. The secretions are stimulated mainly in three phases based on where the signal originates (brain, stomach and intestines). Seeing, smelling, and tasting food are the cephalic / brain phases, which stimulate secretions through the vagal nerves[29][30]. The gastric phase is activated when food enters the stomach which directly stimulates G cells to release gastrin, which in turn activates parietal cells. The stretching of the stomach wall also causes gastrin release and acid production. The hormone somatostatin is released from D cells in the gastric mucosa in response to HCl. Somatostatin directly inhibits acid production from parietal cells or indirectly decreases the release of histamine from ECL and gastrin from G cells. The final phase begins when food enters the intestine and is mediated by lumen stretching and assimilation of nutrients. This situation took place simultaneously[31]

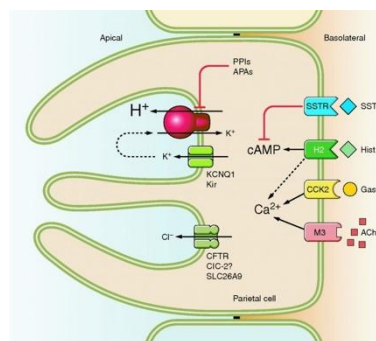


Figure 3 HCL Secretion Mechanism[32]

The mechanism of gastric ulcer based on its pathophysiology is known as three theories: (1) The stomach acid factor "No Acid no Ulcer" Schwarst1910. Parietal / oxyntic cells secrete stomach acid, peptic / zymogen cells secrete pepsinogen which is converted by HCl to pepsin, both of which are aggressive factors. (2) Balance Theory 1974. Ulcers occur when there is a disturbance of balance between aggressive / acidic factors and pepsin

with defensive factors (mucus, bicarbonate, blood flow, prostaglandins), aggressive factors can increase or defensive factors decrease. (3) *Helicobacter pylori* (HP), "No HP no Ulcer" Warren and Marshall 1983[33][34][35].

Helicobacter pylori is a gram-negative rod / spiral, flagellated, living on the surface of the epithelium, containing urease. *Helicobacter pylori* infection can cause chronic gastritis followed by atrophy of the corpus and gland mucosa, intestinal metaplasia, and hypoacidity. In principle, gastric ulcers when viewed from the aspect of lesions, wounds and the healing process are the same as other tissues[36][37][38]. The occurrence of necrosis due to ischemia in the gastric mucosa, free radical formation, and reduced nutrition due to vascular and microvascular injuries will stimulate the release of Leukotrin B4 attracting leukocytes and macrophages, which phagocyte necrotic tissue, and release proinflammatory cytokines such as TNF α , IL-1 α , and IL-1 β which will activate local fibroblasts, endothelial, and epithelial cells. There are two main components found in gastric ulcers, namely the elevated edge of the ulcer formed by adjacent non-necrotic epithelial components, and granulation tissue at the base of the ulcer, which is composed of fibroblasts, macrophages, and proliferation of endothelial cells that form microvascular blood vessels[39][40].

IV. CONCLUSION

Giving Jintan Hitam oil extract at the right dose is effective in reducing the incidence of gastric ulcers and there is no significant difference between giving Jintan Hitam oil extract and giving chemical treatment in the incidence of gastric ulcers. It is necessary to consider giving black cumin extract to patients with gastric ulcers who are allergic and resistant to chemical treatment.

REFERENCES

- [1] M. M. H. Al-Gayyar, H. M. Hassan, A. Alyoussef, A. Abbas, M. M. Darweish, and A. A. El-Hawwary, "Nigella sativa oil attenuates chronic nephrotoxicity induced by oral sodium nitrite: Effects on tissue fibrosis and apoptosis," *Redox Rep.*, vol. 21, no. 2, pp. 50–60, 2016, doi: 10.1179/1351000215Y.0000000035.
- [2] A. C. Ford, K. S. Gurusamy, B. Delaney, D. Forman, and P. Moayyedi, "Eradication therapy for peptic ulcer disease in *Helicobacter pylori*-positive people," *Cochrane Database Syst. Rev.*, vol. 2016, no. 4, 2016, doi: 10.1002/14651858.CD003840.pub5.
- [3] D. Y. Graham, "History of *Helicobacter pylori*, duodenal ulcer, gastric ulcer and gastric cancer," *World J. Gastroenterol.*, vol. 20, no. 18, pp. 5191–5204, 2014, doi: 10.3748/wjg.v20.i18.5191.
- [4] M. C. Mat, A. S. Mohamed, and S. S. Hamid, "Primary human monocyte differentiation regulated by Nigella sativa pressed oil," *Lipids Health Dis.*, vol. 10, no. 1, p. 216, 2011, doi: 10.1186/1476-511X-10-216.
- [5] M. Zalecki, "Gastric ulcer induced changes in substance P and Nk1, Nk2, Nk3 receptors expression in different stomach localizations with regard to intrinsic neuronal system," *Histochem. Cell Biol.*, vol. 151, no. 1, pp. 29–42, 2019, doi: 10.1007/s00418-018-1715-4.
- [6] M. Balbaa, S. A. Abdulmalek, and S. Khalil, "Oxidative stress and expression of insulin signaling proteins in the brain of diabetic rats: Role of Nigella sativa oil and antidiabetic drugs," *PLoS One*, vol. 12, no. 5, pp. 1–23, 2017, doi: 10.1371/journal.pone.0172429.
- [7] M. Magierowski *et al.*, "Carbon monoxide released from its pharmacological donor, tricarbonyldichlororuthenium (II) dimer, accelerates the healing of pre-existing gastric ulcers," *Br. J. Pharmacol.*, vol. 174, no. 20, pp. 3654–3668, 2017, doi: 10.1111/bph.13968.
- [8] E. Razmpoosh *et al.*, "Effects of oral Nigella sativa oil on the expression levels and serum concentrations

- of adiponectin, PPAR- γ , and TNF- α in overweight and obese women: A study protocol for a crossover-designed, double-blind, placebo-controlled randomized clinical trial,” *Trials*, vol. 20, no. 1, pp. 1–8, 2019, doi: 10.1186/s13063-019-3568-0.
- [9] Z. Cheng *et al.*, “Fabrication of ulcer-adhesive oral keratin hydrogel for gastric ulcer healing in a rat,” *Regen. Biomater.*, vol. 8, no. 2, pp. 1–11, 2021, doi: 10.1093/rb/rbab008.
- [10] S. W. Mansour, S. Sangi, S. Harsha, M. A. Khaleel, and A. R. N. Ibrahim, “Sensibility of male rats fertility against olive oil, Nigella sativa oil and pomegranate extract,” *Asian Pac. J. Trop. Biomed.*, vol. 3, no. 7, pp. 563–568, 2013, doi: 10.1016/S2221-1691(13)60114-8.
- [11] K. Saremi, S. K. Rad, M. Khalilzadeh, J. Hussaini, and N. A. Majid, “In vivo acute toxicity and anti-gastric evaluation of a novel dichloro Schiff base: Bax and HSP70 alteration,” *Acta Biochim. Biophys. Sin. (Shanghai)*, vol. 52, no. 1, pp. 26–37, 2020, doi: 10.1093/abbs/gmz140.
- [12] R. Agbaria, A. Gabarin, A. Dahan, and S. Ben-Shabat, “Anticancer activity of Nigella sativa (black seed) and its relationship with the thermal processing and quinone composition of the seed,” *Drug Des. Devel. Ther.*, vol. 9, pp. 3119–3124, 2015, doi: 10.2147/DDDT.S82938.
- [13] H. M. Ali Sidahmed *et al.*, “Evidence of the gastroprotective and anti-helicobacter pylori activities of β -mangostin isolated from *Cratoxylum arborescens* (Vahl) blume,” *Drug Des. Devel. Ther.*, vol. 10, pp. 297–313, 2016, doi: 10.2147/DDDT.S80625.
- [14] M. Lang *et al.*, “Thymoquinone attenuates tumor growth in ApcMin mice by interference with Wnt-signaling,” *Mol. Cancer*, vol. 12, no. 1, p. 1, 2013, doi: 10.1186/1476-4598-12-41.
- [15] P. Dharmani, C. De Simone, and K. Chadee, “The Probiotic Mixture VSL#3 Accelerates Gastric Ulcer Healing by Stimulating Vascular Endothelial Growth Factor,” *PLoS One*, vol. 8, no. 3, 2013, doi: 10.1371/journal.pone.0058671.
- [16] İ. Kahramanoğlu, M. Aktas, and Ş. Gündüz, “Effects of fludioxonil, propolis and black seed oil application on the postharvest quality of ‘Wonderful’ pomegranate,” *PLoS One*, vol. 13, no. 5, pp. 1–14, 2018, doi: 10.1371/journal.pone.0198411.
- [17] Y. C. Chen, C. C. Ho, C. H. Yi, X. Z. Liu, T. T. Cheng, and C. F. Lam, “Exendin-4, a glucagon-like peptide-1 analogue accelerates healing of chronic gastric ulcer in diabetic rats,” *PLoS One*, vol. 12, no. 11, pp. 1–13, 2017, doi: 10.1371/journal.pone.0187434.
- [18] E. M. F. Barakat, L. M. El Wakeel, and R. S. Hagag, “Effects of Nigella sativa on outcome of hepatitis C in Egypt,” *World J. Gastroenterol.*, vol. 19, no. 16, pp. 2529–2536, 2013, doi: 10.3748/wjg.v19.i16.2529.
- [19] W. P. Bi, H. Bin Man, and M. Q. Man, “Efficacy and safety of herbal medicines in treating gastric ulcer: A review,” *World J. Gastroenterol.*, vol. 20, no. 45, pp. 17020–17028, 2014, doi: 10.3748/wjg.v20.i45.17020.
- [20] C. Nasuti, L. Bordoni, D. Fedeli, and R. Gabbianelli, “Effect of Nigella sativa Oil in a Rat Model of Adjuvant-Induced Arthritis,” *Proceedings*, vol. 11, no. 1, p. 16, 2019, doi: 10.3390/proceedings2019011016.
- [21] K. Saremi, S. K. Rad, F. Tayeby, M. A. Abdulla, H. Karimian, and N. A. Majid, “Gastroprotective activity of a novel Schiff base derived dibromo substituted compound against ethanol-induced acute gastric lesions in rats,” *BMC Pharmacol. Toxicol.*, vol. 20, no. 1, pp. 1–13, 2019, doi: 10.1186/s40360-019-0292-z.
- [22] A. Mouwakeh, Á. Telbisz, G. Spengler, C. Mohácsi-Farkas, and G. Kiskó, “Antibacterial and resistance

- modifying activities of nigella sativa essential oil and its active compounds against listeria monocytogenes,” *In Vivo (Brooklyn)*, vol. 32, no. 4, pp. 737–743, 2018, doi: 10.21873/invivo.11302.
- [23] A. M. Mousa *et al.*, “Antiulcerogenic effect of Cuphea ignea extract against ethanol-induced gastric ulcer in rats,” *BMC Complement. Altern. Med.*, vol. 19, no. 1, pp. 1–13, 2019, doi: 10.1186/s12906-019-2760-9.
- [24] M. A. Toama, T. S. El-Alfy, and H. M. El-Fatraty, “Antimicrobial activity of the volatile oil of Nigella sativa Linneaus seeds,” *Antimicrob. Agents Chemother.*, vol. 6, no. 2, pp. 225–226, 1974, doi: 10.1128/AAC.6.2.225.
- [25] X. Ha *et al.*, “Enhancement of gastric ulcer healing and angiogenesis by hepatocyte growth factor gene mediated by attenuated salmonella in rats,” *J. Korean Med. Sci.*, vol. 32, no. 2, pp. 186–194, 2017, doi: 10.3346/jkms.2017.32.2.186.
- [26] W. D. Chey, B. E. Lacy, B. D. Cash, M. Epstein, P. E. Corsino, and S. M. Shah, “A novel, duodenal-release formulation of a combination of caraway oil and l-menthol for the treatment of functional dyspepsia: A randomized controlled trial,” *Clin. Transl. Gastroenterol.*, vol. 10, no. 4, pp. 1–9, 2019, doi: 10.14309/ctg.0000000000000021.
- [27] W. L. Huang, Y. G. Li, Y. C. Lv, X. H. Guan, H. F. Ji, and B. R. Chi, “Use of lectin microarray to differentiate gastric cancer from gastric ulcer,” *World J. Gastroenterol.*, vol. 20, no. 18, pp. 5474–5482, 2014, doi: 10.3748/wjg.v20.i18.5474.
- [28] H. H. Idrus, M. Hatta, and Budu, “Role of High Motility Group Box 1 (HMGB-1) in Inflammation on Salmonella Typhi Bacterial Infection,” in *Online International Conference on Life Sciences (OICLS-20)*, 2020, vol. 1, pp. 1–11.
- [29] M. Mahboubi, “Caraway as Important Medicinal Plants in Management of Diseases,” *Nat. Products Bioprospect.*, vol. 9, no. 1, pp. 1–11, 2019, doi: 10.1007/s13659-018-0190-x.
- [30] E. Aihara *et al.*, “Motility and Chemotaxis Mediate the Preferential Colonization of Gastric Injury Sites by Helicobacter pylori,” *PLoS Pathog.*, vol. 10, no. 7, 2014, doi: 10.1371/journal.ppat.1004275.
- [31] N. K. Mohammed, B. J. Muhiaddin, and A. S. Meor Hussin, “Characterization of nanoemulsion of Nigella sativa oil and its application in ice cream,” *Food Sci. Nutr.*, vol. 8, no. 6, pp. 2608–2618, 2020, doi: 10.1002/fsn3.1500.
- [32] S. S. Zaghlool, A. A. Abo-Seif, M. A. Rabeh, U. R. Abdelmohsen, and B. A. S. Messiha, *Gastro-protective and anti-oxidant potential of Althaea officinalis and Solanum nigrum on pyloric ligation/indomethacin-induced ulceration in rats*, vol. 8, no. 11. 2019.
- [33] K. A. Abdel-Sater, “Gastroprotective effects of Nigella Sativa oil on the formation of stress gastritis in hypothyroidal rats,” *Int. J. Physiol. Pathophysiol. Pharmacol.*, vol. 1, no. 2, pp. 143–149, 2009.
- [34] J. U. Park, J. H. Kang, M. A. A. Rahman, A. Hussain, J. S. Cho, and Y. I. Lee, “Gastroprotective Effects of Plants Extracts on Gastric Mucosal Injury in Experimental Sprague-Dawley Rats,” *Biomed Res. Int.*, vol. 2019, 2019, doi: 10.1155/2019/8759708.
- [35] H. H. Idrus, M. Hatta, A. Febriza, and V. N. A. Kasim, “Antibacterial activities of sapodilla fruit extract inhibiting Salmonella typhi on mice BALB/c,” *Int. J. Appl. Pharm.*, vol. 11, no. Special Issue 5, pp. 121–126, Sep. 2019, doi: 10.22159/ijap.2019.v11s5.T0095.
- [36] M. N. Al-Seeni, H. A. El Rabey, A. M. Al-Hamed, and M. A. Zamazami, “Nigella sativa oil protects against tartrazine toxicity in male rats,” *Toxicol. Reports*, vol. 5, no. May 2017, pp. 146–155, 2018, doi:

10.1016/j.toxrep.2017.12.022.

- [37] H. H. Idrus *et al.*, “Molecular impact on high motility group box-1 (HMGB-1) in pamps and damp,” *Indian J. Public Heal. Res. Dev.*, 2019, doi: 10.5958/0976-5506.2019.02045.X.
- [38] H. H. Idrus and Y. Mangarengi, “Effectiveness of Tuberculosis Control by Including Dots in the Scope of Work of Tamalanrea Puskesmas of 2010,” 2018, [Online]. Available: <http://proceeding.sari-mutiara.ac.id/index.php/samicoh>.
- [39] M. H. Farzaei, M. Abdollahi, and R. Rahimi, “Role of dietary polyphenols in the management of peptic ulcer,” *World J. Gastroenterol.*, vol. 21, no. 21, pp. 6499–6517, 2015, doi: 10.3748/wjg.v21.i21.6499.
- [40] F. Tayeby, A. A. A. Salman, S. Kamran, S. L. Khaing, N. B. Salehen, and G. M. A. D. Mohan, “Ulcer prevention effect of 3,4,5-tihydroxy-N0-[(2-methyl-1H-indol-3yl)methylidene]benzohydrazide in HCl/ethanol-induced gastric mucosal damage in rats,” *Int. J. Med. Sci.*, vol. 14, no. 13, pp. 1317–1326, 2017, doi: 10.7150/ijms.20984.
- [41] Y. Sari, I. Purnawan, D. W. Kurniawan, and E. Sutrisna, “A comparative study of the effects of nigella sativa oil gel and aloe Vera gel on wound healing in diabetic rats,” *J. Evidence-Based Integr. Med.*, vol. 23, pp. 1–6, 2018, doi: 10.1177/2515690X18772804.
- [42] H. H. Idrus *et al.*, “Achras Zapota L Extract Reduces Levels of Soluble Tumor Necrosis Alpha (TNF-a) of Salmonella Typhi,” 2019.