



## **Efficacy of Treatment of Patients With Chronic Dacryocystitis And Features of the Late Postoperative Period**

O. Minaiev

Department of otorhinolaryngology, Donetsk national medical university of Ministry of Health of Ukraine, Kramatorsk, Ukraine

---

**Abstract:** Chronic dacryocystitis is a fairly common pathology of the nasolacrimal ducts. The study included 109 patients with chronic dacryocystitis, who were examined and restored lacrimal passage by performing endonasal endoscopic dacryocystorhinostomy. In the late postoperative period, the severity of lacrimation was determined by the P.L.Munk scale, the degree of dacryostoma imaging was assessed, and lacrimal function was determined. One year after endonasal endoscopic dacryocystorhinostomy, the final efficacy of treatment was evaluated. Significantly better results were in the group of patients who used the developed method of endonasal endoscopic dacryocystorhinostomy. It was found that the lacrimal implant and preserved mucosal flaps have a negative effect on the restoration of tearing in the late postoperative period. Deterioration of lacrimal function and recurrence of the disease most often occur from the 3rd to the 6th month after undergoing dacryocystorhinostomy, during which time patients need active monitoring.

**Keywords** – *chronic dacryocystitis, endonasal endoscopic dacryocystorhinostomy*

---

### **I. INTRODUCTION**

Chronic dacryocystitis is a fairly common pathology of the nasolacrimal ducts. Timely diagnosis and then adequate treatment with the use of modern minimally invasive technologies is the key to faster recovery and sustainable recovery of tearing. However, despite the significant achievements of science and technology, effective treatment of lacrimal duct pathology remains an urgent problem of modern ophthalmology and rhinology. Endonasal endoscopic dacryocystorhinostomy (EEDCR) has a number of undeniable advantages: no cosmetic defect, relatively short duration of operation, anatomical features and anomalies of intranasal structures are taken into account and, if necessary, their simultaneous correction, short postoperative period with much less pain [1-6].

There are many modifications of EEDCR, but the search for the optimal one, which gives a lower recurrence rate, remains relevant [2, 4, 7-12]. The cause of recurrence of the disease is excessive growth of granulation tissue in the area of postoperative dacryostoma and its overgrowth. Much attention is paid to the study of the late postoperative period, because it is during this period, as a rule, there is a recurrence of the disease and reduced quality of life. The aim of our study was to evaluate the effectiveness of treatment of patients with chronic dacryocystitis in their observation in the late postoperative period.

### **II. MATERIAL AND METHODS**

The study included 109 patients with chronic dacryocystitis, who were examined and operated in the period 2004-2019 years, in the Department of Otorhinolaryngology (Faculty of Internship and Postgraduate Education, Donetsk National Medical University of the Ministry of Health of Ukraine). Of these, 86 women and 23 men aged 18 to 78 years (average,  $49.1 \pm 16.2$  years). The duration of complaints of tearing ranged from 2 months to 9 years. In all patients, chronic dacryocystitis was dormant. All patients underwent restoration of lacrimal passage by performing endonasal endoscopic dacryocystorhinostomy (EEDCR).

Depending on the modification in which the EEDCR was performed, all patients were divided into 3 groups: the 1st group (study group) consisted of 45 patients who underwent EEDCR according to our technique. The 2nd (comparison group) included 36 patients who, after performing the EEDCR developed by us, had a polyvinyl chloride (PVC) conductor installed in the lacrimal ducts. The 3rd (control) group included 28 patients who

underwent EEDCR according to the generally accepted technique: with preservation and plastic stacking of the cut flaps of the mucous membrane of the nasal cavity and lacrimal sac and with the installation of a PVC-conductor.

Differences of the proposed EEDCR technique: at the stage of cutting out the U-shaped flap of the nasal mucosa, the incision site was first identified by diaphanoscopy, at the stage of opening the lacrimal sac the latter was cut to the bottom (maximum down), and the cut flaps of the lateral wall of nasal cavity and medial wall lacrimal sac were cut out.

The distribution of patients by clinical groups and subgroups are presented in table 1.

Table 1. Distribution of patients by clinical groups according to preoperative radiological examination and performed surgical treatment

№	Clinical group		Surgical treatment	Preoperative examination
1	Study group	A	Endonasal Endoscopic Dacryocystorhinostomy according to the proposed method	Computed Tomography lacrimal ducts with contrast according to the proposed method
		B		Computed Tomography lacrimal ducts by the traditional method
2	Comparison group	A	Endonasal Endoscopic Dacryocystorhinostomy according to the proposed method + lacrimal implant	Computed Tomography lacrimal ducts with contrast according to the proposed method
		B		Computed Tomography lacrimal ducts by the traditional method
3	Control group		Endonasal Endoscopic Dacryocystorhinostomy by the traditional method	

In the late postoperative period, all patients were examined at 1, 3, 6 and 12 months. In patients of the 2nd and 3rd clinical groups, the PVC-conductor was removed from the lacrimal ducts after 1.5 months. The severity of lacrimation was assessed by testing according to the P.L. Munk scale. At each visit to the patient during endoscopic examination of the nasal cavity was assessed the degree of visualization of dacryostomy and the condition of the mucous membrane in the area of dacryostoma and the middle nasal meatus on the basis of its edema according to the criteria specified in the modified scale of Lund and Kennedy. At this time, the lacrimal function was determined by advanced West nasolacrimal test under endoscopic control.

The results of the final treatment of patients with chronic dacryocystitis were assessed 1 year after surgery according to the criteria that determine the indicators of "recovery" (the severity of lacrimation 0 points on the Munk scale, good visualization of the formed dacryostoma, positive function of lacrimation), "improvement" (the severity of lacrimation on the Munk scale 1-2 points, reduced visualization of the formed dacryostoma, delayed or positive lacrimation function) and "disease recurrence" (assessment of the severity of lacrimation on the Munk scale from 3 to 5 points, no visualization of dacryostoma, negative lacrimal function).

### III. RESULTS AND DISCUSSION

The early postoperative period was uneventful, lacrimal function was restored in each patient. Data on the the severity of lacrimation on the Munk scale are shown in table 2.

Table 2. The severity of lacrimation in patients with chronic dacryocystitis in the late postoperative period according to testing on the Munk scale, the mean score

Terms	Groups				
	1A**	1B**	2A**	2B**	3**
<b>Before treatment</b>	3,464±0,693	3,529±0,717	3,571±0,676	3,533±0,743	3,429±0,69
<b>1 month*</b>	0,714±0,713	0,882±0,781	1,476±0,602	1,533±0,743	1,714±0,535
<b>3 months</b>	0,679±0,723	0,941±0,827	0,905±0,7	0,867±0,834	1,0±0,72
<b>6 months</b>	0,571±0,634	0,706±0,686	0,619±0,669	0,667±0,724	0,893±0,685
<b>12 months</b>	0,536±0,637	0,588±0,618	0,619±0,669	0,667±0,724	0,893±0,685

\* - the difference between the groups is statistically significant, the criterion  $\chi^2$

\*\* - the difference in repeated measurements is statistically significant, Friedman criterion,  $p < 0,001$

Before treatment, the average score on the severity of lacrimation on the Munk scale in patients of all groups was quite high and was more than 3.4 points. In the statistical analysis, no significant difference in the mean score before treatment between groups was detected ( $p > 0.05$ ), and patients were evenly distributed between groups.

At the follow-up of 1 month, the average score was higher in groups 2A, 2B and № 3, lower in groups 1A and 1B (the difference is statistically significant,  $p < 0,05$ ). During the observation period of 3 months, i.e after removal of the implant from the lacrimal ducts in patients of groups 2A, 2B and № 3, the average score in these groups decreased significantly, and comparing the dynamics with the observation period of 1 month, the difference was statistically significant ( $p < 0.001$ ). During the observation period of 3 months and the following period, the average scores were equalized among all groups, and in the statistical analysis no significant difference was found between all groups ( $p > 0.05$ ). At the same time, in group №3 in all terms of observation of the late postoperative period the average score was the highest, but due to insufficient statistical power to achieve statistical no significant difference between groups ( $p > 0.05$ ).

The degree of edema of the middle nasal meatus and dacryotoma area in patients of all groups in the late postoperative period is shown in Figure 1.

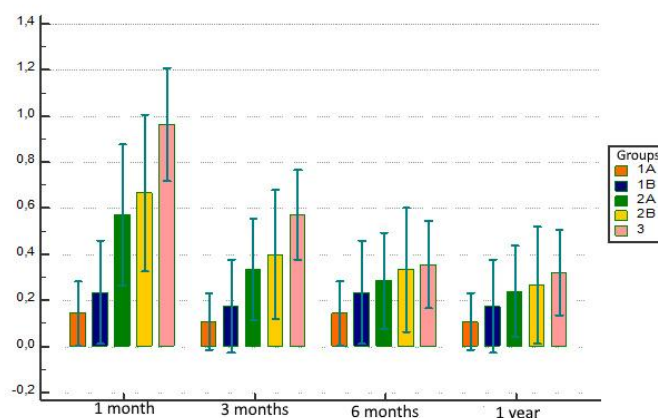


Fig. 1. The degree of edema of the middle nasal meatus and dacryostoma area in patients of all groups in the late postoperative period.

As can be seen from the combined diagram in Figure 1, at 1 and 3 months in groups 1A and 2A the edema of the mucous membrane was statistically significant ( $p < 0,05$ ) better than in groups 2A, 2B and № 3, and at 6 months and at 1 year no significant difference was found ( $p > 0.05$ ). Thus, it is possible to conclude about the negative impact of the implant in the lacrimal ducts in the observation period of 1 month and the improvement of the mucous membrane of the dacryostoma area and the middle nasal meatus after its removal. At the 6th month of observation, the mucous membrane of all groups was restored, and its degree of edema was leveled and became comparable among patients of all groups.

Endoscopic examination of the nasal cavity evaluated the visualization of dacryostoma (Fig. 2, 3, 4, 5).

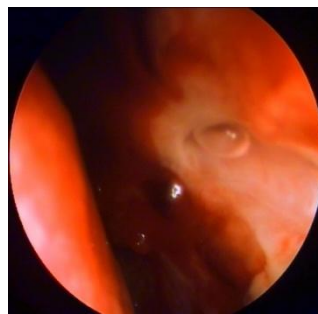

Fig. 2. Patient M. from group 1A, two weeks after surgery: the formed dacryostoma is well visualized, the passage of a tear with an air bubble is noted as the proof of the kept tear-removing function during a blinking.

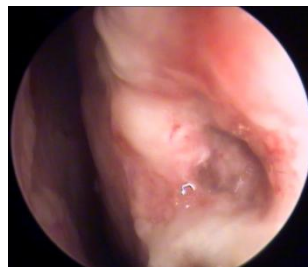

Fig. 3. Patient P. from group 1B, 1 month after surgery: the formed dacryostoma is well visualized, there is a moderate amount of granulation around the dacryostoma.

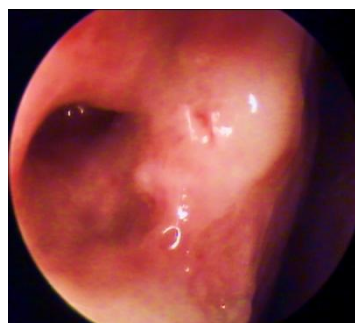

Fig. 4. Patient F. from group 1A, 3 months after the operation: the formed dacryostoma is well visualized, it in small amount of flowing tears.

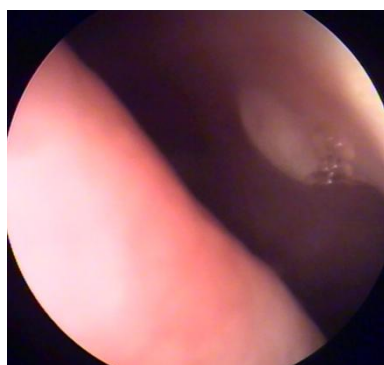


Fig. 5. Patient P. from group 2A, 1 year after surgery: formed dacryostoma slightly reduced imaging, air bubbles near dacryostoma.

In the early postoperative period, visualization of dacryostoma was good in all patients. In the late postoperative period this indicator is shown in tables 3, 4, 5 and 6.

Table 3. The degree of visualization of dacryostoma, 1 month after surgery

Groups	1A		1B		2A		2B		3	
	n=28		n=17		n=21		n=15		n=28	
	abs.	%	abs.	%	abs.	%	abs.	%	abs.	%
Good	26	92,9	14	82,4	19	90,5	12	80	19	67,9
Reduced	2	7,1	3	17,6	2	9,5	3	20	9	32,1

As can be seen from the data in Table 3, the best results were in group 1A, the worst - in group №3, but without statistical significance due to the small sample of patients ( $p > 0.05$ ). At the same time, in the control clinical group there was a relatively high percentage of patients with reduced imaging of dacryostoma. No patient during this observation period had difficulty in visualizing postoperative dacryostoma, which coincided with the absence of recurrence of the disease in all groups.

Table 4. The degree of visualization of dacryostoma, 3 months after surgery

Groups	1A		1B		2A		2B		3	
	n=28		n=17		n=21		n=15		n=28	
	abs.	%	abs.	%	abs.	%	abs.	%	abs.	%
Good	25	89,3	13	76,5	18	85,7	11	73,3	17	60,7
Reduced	3	10,7	4	23,5	3	14,3	4	26,7	10	35,7
Clearly not visualized	0	0	0	0	0	0	0	0	1	3,6

At a follow-up of 3 months, this figure deteriorated slightly in all clinical groups. In group №3 there was a higher percentage of patients with reduced visualization compared to other groups, but without a statistically significant difference ( $p > 0.05$ ). However, in group № 3 in one patient (3.6%) visualization of the dacryostoma was absent, which coincided with the recurrence of dacryocystitis.

Table 5. The degree of visualization of dacryostoma, 6 months after surgery

Groups	1A		1B		2A		2B		3	
	n=28		n=17		n=21		n=15		n=28	
	aбс.	%	aбс.	%	aбс.	%	aбс.	%	aбс.	%
Good	24	85,7	12	70,6	17	81	10	66,7	14	50
Reduced	4	14,3	4	23,5	3	14,3	4	26,7	11	39,3
Clearly not visualized	0	0	1	5,9	1	4,7	1	6,6	3	10,7

Six months after surgery, a faster rate of deterioration in dacryostoma imaging was observed in all clinical groups compared. In groups 1B, 2A and 2B at this time of observation there were patients in whom clear visualization of postoperative dacryostoma was absent, and in the control group – an increase in such patients by 2 (7.1%). The best indicators were noted in group 1A, the worst results were recorded in group №3, but without statistical significance ( $p > 0.05$ ).

Table 6. The degree of visualization of dacryostoma, 12 months after surgery

Groups	1A		1B		2A		2B		3	
	n=28		n=17		n=21		n=15		n=28	
	aбс.	%	aбс.	%	aбс.	%	aбс.	%	aбс.	%
Good	24	85,7	11	64,7	16	76,2	9	60	14	50
Reduced	4	14,3	5	29,4	4	19	5	33,3	10	35,7
Clearly not visualized	0	0	1	5,9	1	4,8	1	6,7	4	14,3

One year after surgery, the best imaging of dacryostoma was in group 1A patients, and a higher percentage of patients in whom dacryostoma was not clearly visualized was in group №3, but due to a small sample of patients, statistical significance was not achieved in differences between groups ( $p > 0,05$ ). However, there is a clear trend that in group 1A the visualization index was better than in other groups. Thus, it should be noted that the maximum rate of deterioration of dacryostoma imaging, including the absence of imaging, was observed from the 3rd to the 6th month after surgery.

The results of lacrimal function during blinking in patients of all groups in the late postoperative period are shown in Figures 6, 7, 8 and 9.

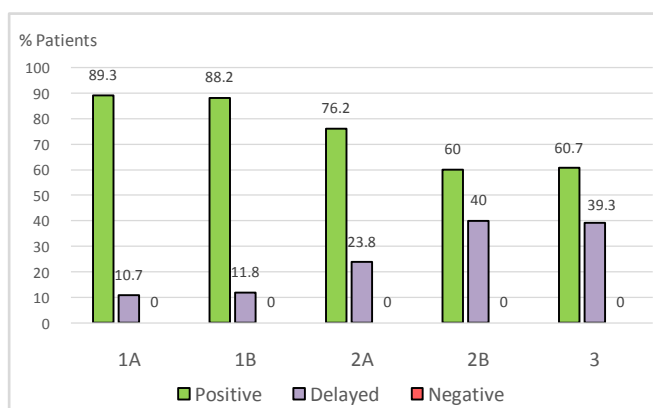


Fig. 6. Lacrimal function during blinking, 1 month after surgery (the difference between the groups is statistically significant,  $P = 0,0486$ , criterion  $\chi^2$ ).

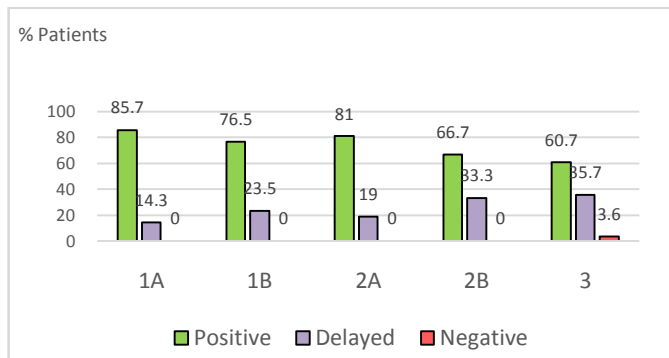


Fig. 7. Lacrimal function during blinking, 3 months after surgery

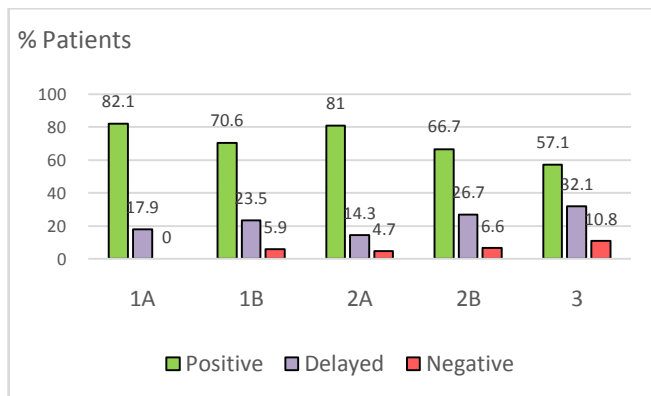


Fig. 8. Lacrimal function during blinking, 6 months after surgery

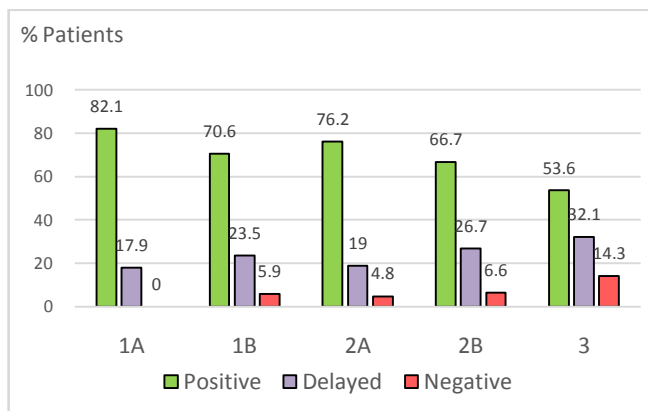


Fig. 9. Lacrimal function during blinking, 12 months after surgery

One month after surgery, the percentage of patients with positive values of lacrimal function in blinking was high in all groups, the best values were observed in groups 1A and 1B in contrast to groups 2A, 2B and №3 (statistically significant difference,  $p < 0,05$ ). Obviously, the worse performance of lacrimal function in groups 2A, 2B and №3 is due to the presence in the lumen of the lacrimal ducts of the conductor, which reduced the lacrimal function.

In subsequent follow-up, this indicator deteriorated slightly in all clinical groups, the best results were in group 1A, the worst - in group №3, but due to a small sample of patients statistically significant differences at 3, 6 and 12 months were not observed ( $p > 0.05$ ). In groups 1B, 2A, 2B and №3, patients with negative values of lacrimal function appeared in these observation periods. Thus, the maximum rate of deterioration of lacrimal function during blinking, including its negative values, was observed from the 3rd to the 6th month.

The final efficacy of the treatment of patients with chronic dacryocystitis 1 year after surgery is shown in table 7 and figure 10.

Table 7. The results of the effectiveness of treatment of patients with chronic dacryocystitis 1 year after surgery

Groups	1 <sup>st</sup> group (n=45)	2 <sup>nd</sup> group (n=36)	3 <sup>rd</sup> group (n=28)
Recovery	35 (77,8 %)	26 (72,2 %)	14 (50,0 %)
Improvement	9 (20 %)	8 (22,2 %)	10 (35,7 %)
Recurrence	1 (2,2 %)	2 (5,6 %)	4 (14,3 %)

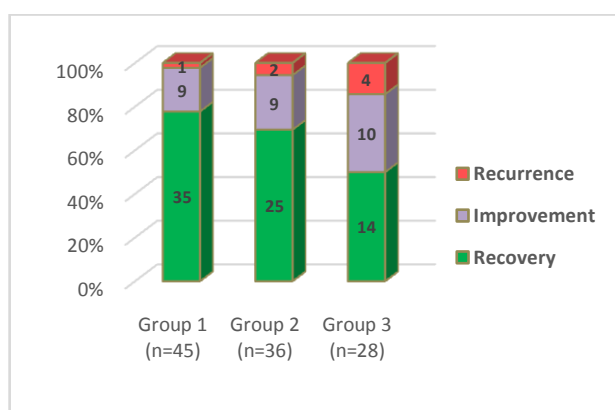


Fig. 10. The effectiveness of treatment in patients of clinical groups 1 year after surgery.

The best indicators of the final effectiveness of treatment were noted in group №1, but there was no statistically significant difference from the 2nd group ( $p > 0.05$ ), and when comparing the 1st and 3rd groups the difference was statistically significant ( $p = 0.0261$ ). Thus, the share of positive results in group 1 was 97.8%, in group 2 was 94.4%, and in group 3 – 85.7%.

It should be noted that in the 1st group the recurrence of the disease occurred in subgroup 1B, and in subgroup 1A we observed only positive results of treatment. At the same time, in group 2 the best functional indicators of tearing were observed in subgroup 2A. Thus, the developed method of computed tomography in the preoperative examination of patients with chronic dacryocystitis is more effective and has a positive effect on the postoperative course, despite the fact that a statistically significant difference could not be achieved ( $p > 0.05$ ).

#### IV. CONCLUSION

1. Lacrimal implant and preserved mucosal flaps adversely affect the recovery of lacrimal function in the late postoperative period.
2. The use of our proposed technique of endonasal endoscopic dacryocystorhinostomy allows to achieve stable remission in 97.8% of patients with chronic dacryocystitis, which is 12.1% higher compared to the control group.
3. Deterioration of lacrimal function and recurrence of the disease most often occur from the 3rd to the 6th month after undergoing dacryocystorhinostomy, during which time patients need active monitoring.



## REFERENCES

- [1] Atkova EL, Yartsev VD, Krahovetskyi NN, Reznikova LV, Root AO, Study of the structural features of the mouth of the nasolacrimal duct according to multislice computed tomography, *Journal of Radiology and Nuclear Medicine*, 99(2), 2018, 63-70. (8) (In Russian).
- [2] Magomedov MM, Borisova OYu, Baharev AV, Lapchenko AA, Magomedova NM, Gadua NT, The multidisciplinary approach to the diagnostics and surgical treatment of the lacrimal passages, *Bulletin of Otorhinolaryngology*, 83(3), 2018, 88-93. (6) (In Russian).
- [3] Piskunov GZ, Piskunov SZ, Kozlov VS, Lopatin AS, Diseases of the nose and paranasal sinuses, *Endomikrosurgery*, 2003, 178-179. (2) (In Russian).
- [4] Kumar S, Mishra AK, Sethi A, Mallick A, Maggon N, Sharma H, Gupta A, Comparing Outcomes of the Standard Technique of Endoscopic DCR with Its Modifications: A Retrospective Analysis, *Otolaryngol Head Neck Surg*, 160(2), 2019, 347-354. (8).
- [5] Li EY, Wong ES, Wong AC, Yuen HK, Primary vs Secondary Endoscopic Dacryocystorhinostomy for Acute Dacryocystitis With Lacrimal Sac Abscess Formation: A Randomized Clinical Trial, *JAMA Ophthalmol*, 135(12), 2017, 1361-1366. (6).
- [6] Shashidhar K, Nagalotimath U, Dixit D, Endoscopic dacryocystorhinostomy with and without silicone stenting: a comparative study, *Al Ameen J Med Sci*, 7(3), 2014, 244-247. (4).
- [7] Beloglazov VG, Atkova EL, Abdurakhmanov GA, Krakhovetskiĭ NN, Prevention of ostial obstruction after microendoscopic endonasal dacryocystorhinostomy, *Vestnik oftal'mologii*. 129(2), 2013, 19-22. (4) (In Russian).
- [8] Baek JS, Jeong SH, Lee JH, Choi HS, Kim SJ, Jang JW, Cause and management of patients with failed endonasal dacryocystorhinostomy. *Clinical and Experimental Otorhinolaryngology*. 10(1), 2017, 85. (1).
- [9] Green R, Gohil R, Ross P, Mucosal and lacrimal flaps for endonasal dacryocystorhinostomy: a systematic review, *Clin Otolaryngol*. 42(3), 2017, 514-520. (7).
- [10] Hodgson N, Bratton E, Whipple K, Priel A, Oh SR, Fante RG, Kikkawa DO, Korn BS, Outcomes of endonasal dacryocystorhinostomy without mucosal flap preservation. *Ophthal Plast Reconstr Surg*. 30(1), 2014, 24-27. (4).
- [11] Shashidhar K, Nagalotimath U, Dixit D, Endoscopic dacryocystorhinostomy with and without silicone stenting: a comparative study, *Al Ameen J Med Sci*, 7(3), 2014, 244-247. (4).
- [12] Wu W, Cannon PS, Yan W, Tu Y, Selva D, Qu J, Effects of Merogel coverage on wound healing and ostial patency in endonasal endoscopic dacryocystorhinostomy for primary chronic dacryocystitis, *Eye (Lond)*. 25(6), 2011, 746-753. (8).